

3-12-2015

## Neuroanatomy Resources

Zachary Sharrow

*The College of Wooster*, [zsharrow@wooster.edu](mailto:zsharrow@wooster.edu)

Follow this and additional works at: <https://openworks.wooster.edu/facpub>

 Part of the [Library and Information Science Commons](#), and the [Nervous System Commons](#)

---

### Recommended Citation

Sharrow, Zachary, "Neuroanatomy Resources" (2015). *Journal of Electronic Resources in Medical Libraries*, 12(1), 83-88. 10.1080/15424065.2015.1001965. Retrieved from <https://openworks.wooster.edu/facpub/189>

This Article is brought to you for free and open access by the All Faculty Scholarship at Open Works, a service of The College of Wooster Libraries. This article is a(n) Accepted Manuscript and was originally published in *Journal of Electronic Resources in Medical Libraries* (2015), available at <http://www.tandfonline.com/doi/abs/10.1080/15424065.2015.1001965>. For questions about OpenWorks, please contact [openworks@wooster.edu](mailto:openworks@wooster.edu).

## **Neuroanatomy Resources**

### *Abstract*

This column will highlight several freely available online resources in neuroanatomy. The featured websites use images, video, animation, and more to create interactive aids for teaching and learning. Because neuroanatomy is a challenging component of all programs of study in medicine and in many allied fields, these resources will be useful for supplementation and self-study in a variety of settings.

## Introduction

Anatomy is among the foundational disciplines for medical professionals; both teachers and students recognize that the cultivation of a robust body of anatomical knowledge is one important outcome of any medical education program.<sup>1</sup> While the nervous system is most closely associated with a few clinical specialties (namely: neurology, neurosurgery, and psychiatry), a working knowledge of neuroanatomy is important for all physicians, as well as other health care professionals encompassing a variety of fields, from dentistry<sup>2</sup> to occupational therapy.<sup>3</sup> At the same time, neuroanatomy can present a number of unique challenges. The central nervous system is complex and highly interconnected, and understanding the relationship between neuropathology and functional deficit requires deep integration of basic and clinical sciences.<sup>4, 5</sup>

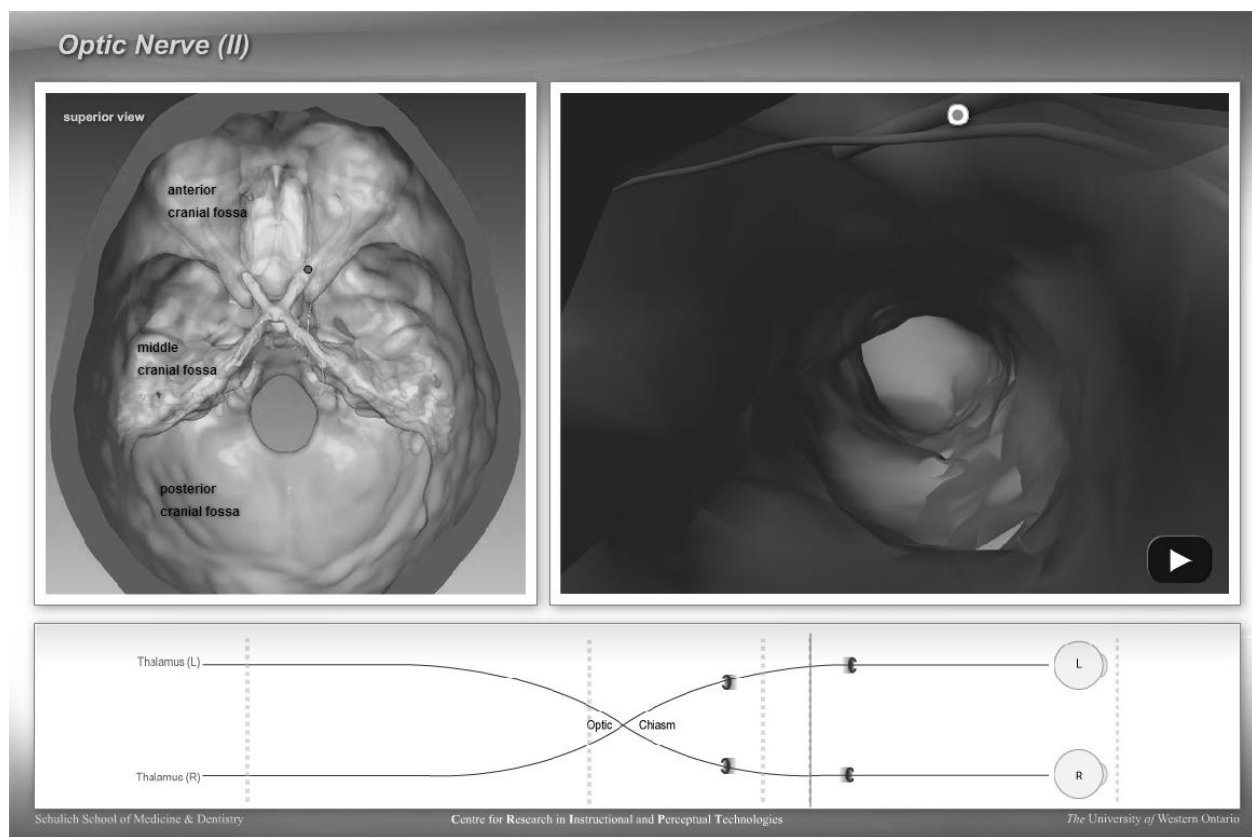
This column will highlight interactive websites that may serve as useful supplements for teaching and learning in neuroanatomy. Special attention will be given to resources that integrate anatomical and functional information or that represent the central nervous system from multiple perspectives, as these integrative approaches have been associated with enhanced learning outcomes.<sup>6</sup>

### The Interactive Web: Examples

#### *Cranial Nerve Experiment*<sup>7</sup>

As the title suggests, this set of tutorials focuses on the sensory and motor functions of the twelve cranial nerves and their paths through the skull. After selecting a nerve (the trigeminal nerve is subdivided by branch), the user is presented with a three-dimensionally rendered skull in two views (Figure 1): an external view marking the pathway of the nerve, and

an internal view, which follows the course of each nerve in a roller coaster-like fashion. A map at the bottom of the window allows users to move forward and backward along the route, and at each of several stops along the way, users can mouse over points of interest to see more information. This website is a creation of the Corps for Research of Instructional and Perceptual Technologies (CRIPT) of the Schulich School of Medicine and Dentistry at the University of Western Ontario, and its development<sup>8</sup> and use in the classroom<sup>9</sup> have been described in the literature. It requires the Adobe Flash Player, which can be freely downloaded online.<sup>10</sup>



**FIGURE 1** Cranial Nerve Experiment. © [Corps for Research of Instructional and Perceptual Technologies]. Reproduced by permission of Corps for Research of Instructional and Perceptual Technologies. Permission to reuse must be obtained from the rightsholder.

*Neurologic Exam: An Anatomical Approach*<sup>11</sup>

This extensive collection of video lessons is divided into units covering a series of neurological exams: mental status exam, cranial nerve exam, coordination exam, sensory exam, motor exam, and gait exam. Each unit includes a series of videos introducing the relevant neuroanatomy, examples of normal and abnormal exams, an interactive quiz, and additional media resources. Anatomical content is presented clearly, and the quizzes require the user to make connections between anatomy and function. The site also includes a series of neurological case studies, in which the user views a case history and a set of results from each of the six exams, creates a checklist of the findings, and identifies the damaged structure(s) (see Figure 2 for an example of step 4: “Localize the Level(s) of the Lesion”). Each case is followed by a thorough discussion.

Neurologic Exam: An Anatomical Approach is hosted by the University of Utah Medical Library and created by Drs. Paul D. Larsen and Suzanne S. Stensaas. Videos require the QuickTime Player, which is a free download.<sup>12</sup>

# NeuroLogical Cases

▶ Menu of Cases



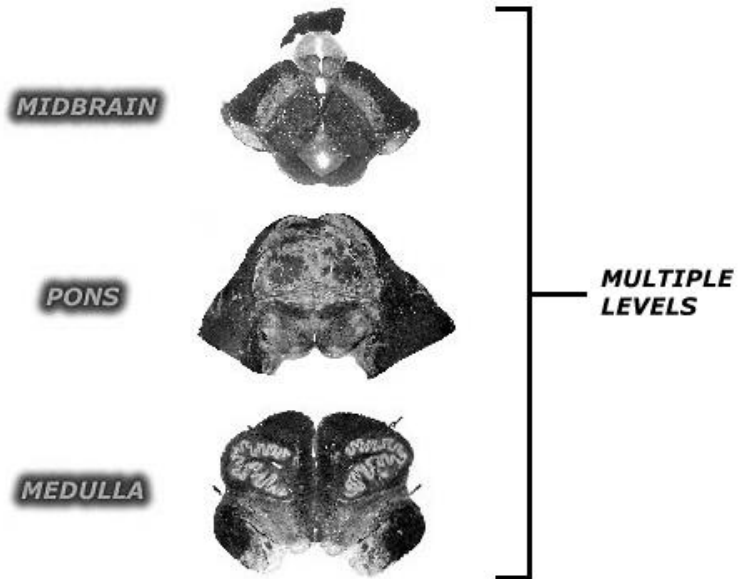
## Case No. 01: The Upset Office Manager

### ▶ Localize the Level(s) of the Lesion

#### Infratentorial "X" Neuroaxis

Continue to localize the lesion for this case. On the diagram, click the level and side you think is involved.

▶ [Return to Localizing on the Y Axis](#)



**FIGURE 2** Example of a Case Study from Neurologic Exam: An Anatomical Approach.

© [Paul D. Larsen, M.D., University of Nebraska Medical Center and Suzanne S. Stensaas, Ph.D., University of Utah School of Medicine]. Reproduced by permission of Paul D. Larsen and Suzanne S. Stensaas. Permission to reuse must be obtained from the rightsholder.

### *HeadNeckBrainSpine: Brain MRI*<sup>13</sup>

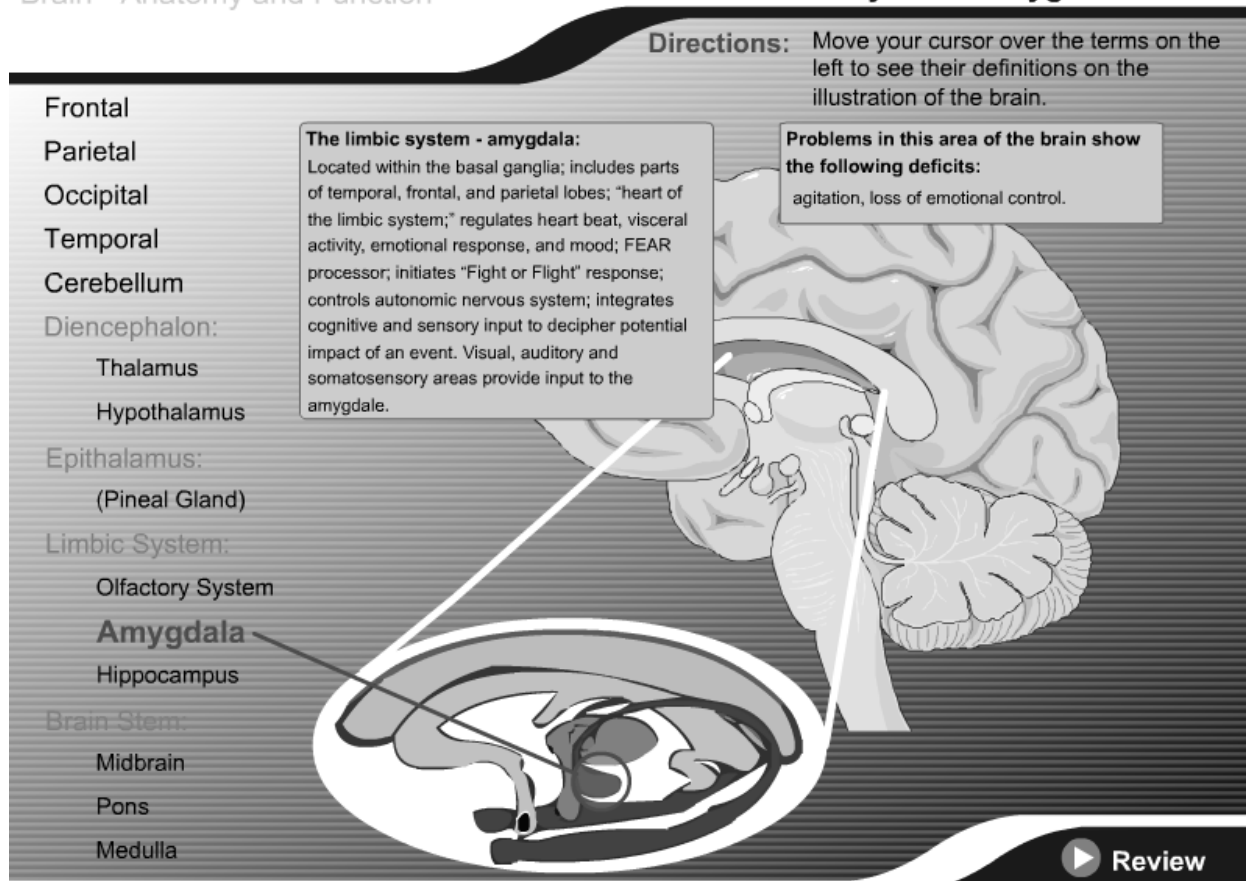
The creator of this tool, Dr. Brett Young, notes that its interface is “meant to mimic a radiology workstation.”<sup>13</sup> Users are able to simultaneously view axial, sagittal, and coronal MRI cross-sections and move smoothly along a single axis using the arrow keys or mouse wheel and

along multiple axes by clicking and dragging. Placing the cursor over a named structure highlights it in each view. Users can also choose to permanently highlight individual structures or groups of related structures (e.g. major sulci or gyri) using a drop down menu. A simple self-quiz is activated by selecting the “quiz mode” option in the top-left.

The HeadNeckBrainSpine website<sup>14</sup> hosts several other neuroradiology modules, as well as hundreds of brief case presentations and downloadable files that can be used to create virtual flash cards. The Adobe Flash Player is required.<sup>10</sup>

*The Brain: Anatomy and Function*<sup>15</sup>

In the first part of this self-contained exercise, users can click on one of fourteen major brain structures to receive detailed information on their normal and abnormal function. Each of the structures is illustrated and highlighted, with cutaway details where appropriate (e.g. the amygdala; see Figure 3). This is followed by a simple matching game in which users drag and drop the name of each structure next to its description. Recommended as a basic review exercise or for those new to the subject, such as undergraduate students, interested patients, or community members, this resource is a creation of the Wisconsin Technical College System. The Adobe Flash Player is required.<sup>10</sup>



**FIGURE 3** The Brain: Anatomy and Function. © [Wisc-Online]. Reproduced by permission of Wisc-Online. Permission to reuse must be obtained from the rightsholder.

### *Other Useful Neuroanatomy Websites*

The University of British Columbia maintains a large and useful neuroanatomy reference designed for undergraduate students with tutorials, videos, and quizzes.<sup>16</sup> The websites BrainMaps.org<sup>17</sup> and TheHumanBrain.info<sup>18</sup> contain a wealth of neuroanatomical data and detailed online atlases, respectively. Those interested in resources for veterinary neuroanatomy will find the University of Minnesota's courseware recommendations invaluable.<sup>19</sup>



## References

1. Bergman, E.M.; van der Vleuten, C.P.M.; and Scherpbier, A.J.J.A. “Why Don’t They Know Enough about Anatomy? A Narrative Review.” *Medical Teacher* 33, no. 5 (2011): 403–9.
2. Klueber, K. M. “Neuroanatomy for the Dentist in the Twenty-First Century.” *Journal of Dental Education* 67, no. 3 (March 1, 2003): 366–69.
3. McKeough, D.M.; Mattern-Baxter, K.; and Barakatt, E. “Effectiveness of a Computer-Aided Neuroanatomy Program for Entry-Level Physical Therapy Students: Anatomy and Clinical Examination of the Dorsal Column-Medial Lemniscal System.” *Journal of Allied Health* 39, no. 3 (2010): 156–64.
4. Hazelton, L. “Changing Concepts of Neuroanatomy Teaching in Medical Education.” *Teaching and Learning in Medicine* 23, no. 4 (October 1, 2011): 359–64.
5. Jozefowicz, R.F. “Neurophobia: The Fear of Neurology among Medical Students.” *Archives of Neurology* 51, no. 4 (April 1, 1994): 328–29.
6. Svirko, E, and Mellanby, J. “Attitudes to E-Learning, Learning Style and Achievement in Learning Neuroanatomy by Medical Students.” *Medical Teacher* 30, no. 9–10 (January 1, 2008): e219–27.
7. Corps for Research of Instructional and Perceptual Technologies. “Cranial Nerve Experiment.” Available: <[http://anatomium.com/CRIPT/cranial\\_nerve\\_experiment.html](http://anatomium.com/CRIPT/cranial_nerve_experiment.html)>. Accessed: November 14, 2014.

8. Yeung, J.C.; Fung, K.; and Wilson, T.D. "Development of a Computer-Assisted Cranial Nerve Simulation from the Visible Human Dataset." *Anatomical Sciences Education* 4, no. 2 (March 1, 2011): 92–97.
9. Yeung, J.C.; Fung, K.; and Wilson, T.D. "Prospective Evaluation of a Web-Based Three-Dimensional Cranial Nerve Simulation." *Journal of Otolaryngology - Head & Neck Surgery* 41, no. 6 (December 2012): 426–36.
10. Adobe. "Adobe – Install Adobe Flash Player." Available: < <http://get.adobe.com/flashplayer/>>. Accessed: November 14, 2014.
11. Larsen, P.D., and Stensaas, S. S. "Neurologic Exam Videos and Descriptions: An Anatomical Approach." Available: < [http://library.med.utah.edu/neurologicexam/html/home\\_exam.html](http://library.med.utah.edu/neurologicexam/html/home_exam.html)>. Accessed: November 13, 2014.
12. Apple Inc. "Apple – Quicktime – Download." Available: < <http://www.apple.com/quicktime/download/>>. Accessed: November 14, 2014.
13. Young, B. "Brain MRI." Available: < <http://headneckbrainspine.com/Brain-MRI.php>>. Accessed: November 13, 2014.
14. Young, B. "HNBS." Available: < <http://headneckbrainspine.com/index.php>>. Accessed: November 14, 2014.
15. Heitman, S. "The Brain – Anatomy and Function." Available: < <https://www.wisc-online.com/learn/career-clusters/health-science/ota502/the-brain---anatomy-and-function>>. Accessed: November 13, 2014.
16. University of British Columbia. "Anatomy of the Brain." Available: < <http://www.neuroanatomy.ca/index.html>>. Accessed: November 14, 2014.
17. BrainMaps.org. "Datasets – Homo Sapiens." Available: < <http://brainmaps.org/>>

- index.php?p=speciesdata&species=homo-sapiens>. Accessed: November 14, 2014.
18. TheHumanBrain.info. "Brain in the Head." Available: < [http://www.thehumanbrain.info/head\\_brain/index.php](http://www.thehumanbrain.info/head_brain/index.php)>. Accessed: November 14, 2014.
  19. University of Minnesota. "Courseware Recommendations – Veterinary Anatomy." Available: < <http://vanat.cvm.umn.edu/CVM6901Recommend.html>>. Accessed: November 14, 2014.